

Case series of four pregnant women with COVID-19 in Ilam, Iran

A. Gheysarzadeh¹, N. Sadeghifard², M. Safari³, T. Rashidian⁴, E. Mohammadyari⁵ and H. Tavan⁶

1) Department of Clinical Biochemistry, 2) Department of Microbiology, School of Medicine, Clinical Microbiology Research Center, 3) Department of Radiology, School of Medicine, Emam Khomeini Hospital, 4) Department of Obstetrics and Gynecology, School of Medicine, Ayatollah Taleghani Hospital, 5) Department of Cardiology, School of Medicine and 6) Department of Medical Surgical Nursing, Clinical Research Development Unit, Shahid Mostafa Khomeini Hospital, Ilam University of Medical Sciences, Ilam, Iran

Abstract

Coronavirus disease 2019 (COVID-19) has quickly become the most important health burden globally as a result of the pandemic. Pregnant women are considered to be in a high-risk group because COVID-19 infection in this group may result in extensive damage. We aimed to describe COVID-19 infections in four pregnant women in Ilam, Iran. All had positive results first by real-time PCR, then by computed tomographic scan. All of these patients were hospitalized, and all of them were treated successfully. This study showed that although pregnant women are at a higher risk of COVID-19 infection, they can be treated successfully. It also demonstrated that receiving care and treatment at the hospital can be a good experience for pregnant women.

© 2020 The Authors. Published by Elsevier Ltd.

Keywords: Corona virus, COVID-19, infection, pandemic, pregnancy

Original Submission: 21 August 2020; **Revised Submission:** 4 October 2020; **Accepted:** 6 October 2020

Article published online: 13 October 2020

Corresponding author: H. Tavan, Clinical Research Development Unit, Shahid Mostafa Khomeini Hospital, Ilam University of Medical Sciences, PO Box 6939177143, Ilam, Iran.
E-mail: hamedtavan@gmail.com

Introduction

Since December 2019, the outbreak of coronavirus disease 2019 (COVID-19) has received much attention, from its first outbreak in China to its spread around the world. World Health Organization statistics indicate that over 30.6 million COVID-19 cases and 950 000 deaths up to 20 September 2020 have been reported [1]. COVID-19 is caused by severe acute respiratory syndrome coronavirus 2 (SARS-CoV-2). Coronavirus is a type of newly described RNA-enveloped virus that can be transmitted via close contact [2–4]. As a result of this infection's high prevalence, the Iranian government decided to close schools, universities and businesses, resulting in great economic losses.

As a result of physiological causes such as immunosuppression, pregnant women are considered to be at high risk for COVID-19 infection [5,6]. The purpose of this study was to report the cases of four pregnant women with COVID-19 in Shahid Mostafa Khomeini Hospital, Ilam, Iran.

Case report

Patient 1

A 27-year-old pregnant woman had been short of breath for 3 days before she sought care. Positive real-time PCR test for COVID-19 was reported. The patient had mild fever; her other vital signs included blood pressure 120/80 mm Hg, respiration rate 14 breaths per minute and heart rate 86 beats per minute. She was conscious. ECG (Fig. 1(A)) and computed tomography (CT) angina were normal (Fig. 2(A)). Clinical

laboratory parameters are summarized in [Table 1](#). The woman's examination revealed nothing abnormal; she was 34 weeks pregnant.

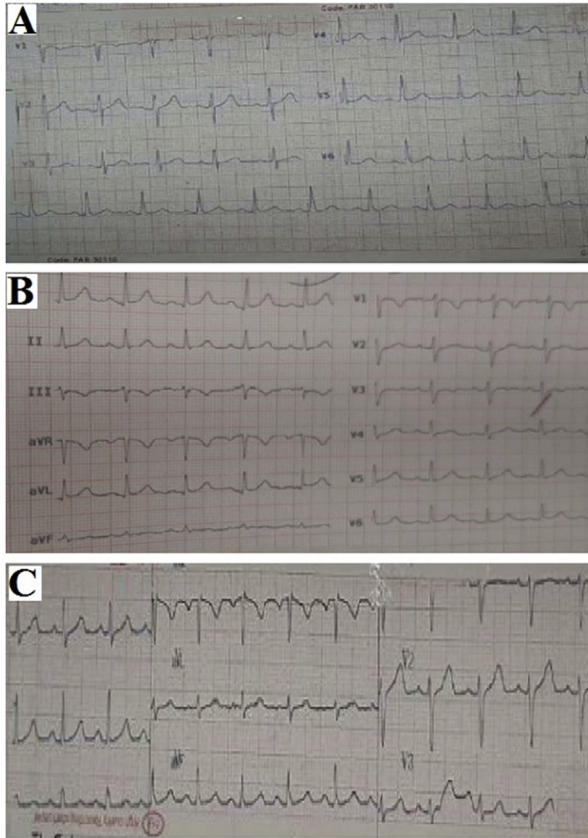


FIG. 1. Electrocardiogram (ECG). (A) Normal sinus rhythm, heart rate 88 bpm, normal axis, no ST-T change, QT normal (400 ms). (B) Normal sinus rhythm, heart rate 100 bpm, normal axis, no ST-T change, QT normal (410 ms). (C) Normal sinus rhythm, heart rate 90 bpm, normal axis, no ST-T change, QT normal (410 ms).

Patient 2

A 30-year-old pregnant woman was hospitalized to treat shortness of breath, fever, cough and abdominal pain. Real-time PCR test for COVID-19 was positive. In the hospital, mild fever (temperature 37.7°C) was evident. Other vital signs were normal, including blood pressure 120/80 mm Hg, respiration rate 19 breaths per minute and heart rate 100 beats per minute. She was conscious, and oxygen saturation was 94%. Imaging was performed by ECG ([Fig. 1\(B\)](#)) and CT scan ([Fig. 2\(B\)](#)). Clinical laboratory parameters are listed in [Table 1](#). The patient's ultrasound revealed in the endometrial cavity a live foetus with a regular heart rate. Pregnancy was estimated, using a measured crown–rump length (CRL) of 53 mm, nuchal translucency of 1.31 mm and biparietal diameter and femur length, to be 22 weeks. The patient was discharged after 3 days' observation with information about warning signs and advice regarding home quarantine.

Patient 3

A 42-year-old pregnant woman underwent a cesarean section 9 days ago. She had been referred to the centre with positive real-time PCR test results. The patient had a fever (38.8°C); the patient's other vital signs were normal, including blood pressure 110/70 mm Hg, respiration rate of 20 breaths per minute and heart rate of 90 beats per minute. The patient was conscious. Oxygen saturation was 96%. The patient did not have a cough, shortness of breath, abdominal pain, sputum, fever, chills or constipation. She was assessed by ECG ([Fig. 1\(C\)](#)). Clinical laboratory test results are listed in [Table 1](#).

Patient 4

A 30-year-old woman pregnant with her first child sought care at the centre and underwent a real-time PCR test, the results of which were positive. The patient had a fever (temperature 38.5°C); other vital signs were normal, with blood pressure

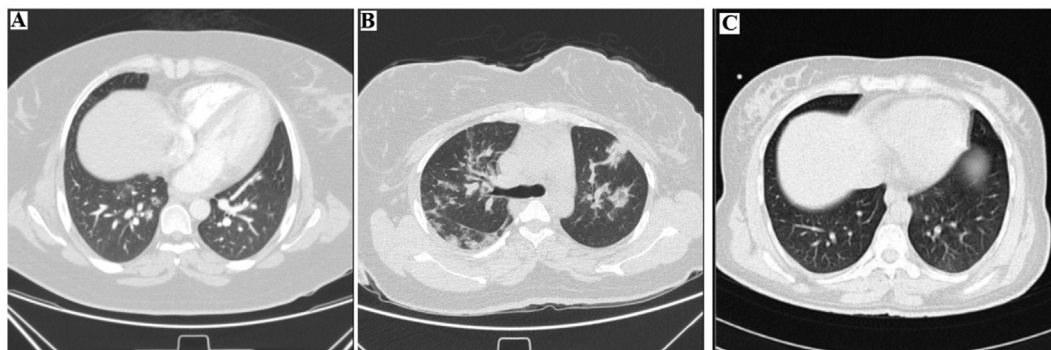


FIG. 2. Chest high-resolution computed tomography (CT). (A) Pulmonary CT angiography to exclude pulmonary thromboembolism. (B) Peripherally predominant airspace consolidations, linear and ground-glass opacities in both side lung fields. (C) Normal lung high-resolution CT.

TABLE 1. Clinical information about pregnant women with coronavirus disease 2019 (COVID-19) in Shahid Mostafa Khomeini Hospital, Ilam, Iran

Clinical variables	First case	Second case	Third case	Fourth case
WBC 10 ³ /μL	6.1	6.2	7.7	
RBC 10 ⁶ /μL	4.41	3.94	4.68	
HB g/dL	11.3	11.3	13.8	
HCT %	34	34.3	43.4	
MCV fL	78	87	93	
MCH pg	25.8	28.2	29.5	
MCHC g/dL	32.2	32.4	31.8	
ESR	-	125	20	13
Platelets 10 ³ /μL	196	199	359	
Neutrophil %	64	81	80	
Lymphocyte %	34	19	18	
Monocyte %	2	-	2	
PT Sec	12	-	-	
PTT Sec	36	-	-	
INR	1	-	-	
CRP	-	-	3+	2+
AST U/L	-	17	-	
ALT U/L	-	12.3	-	
ALK U/L	-	248.8	-	
FBS mg/dL	75	-	-	
Urea mg/dL	11	21	25	
CR mg/dL	0.6	0.8	1	
Na mmol/L	135	138	142	
K mmol/L	3.7	3.9	4.3	
Phosphate mg/dL	1.32	3.4	3.4	
Mg mg/dL	1.76	1.84	2.06	
Camg/dL	10.3	-	8.6	

115/75 mm Hg, respiration rate 18 breaths per minute and heart rate 95 beats per minute. The patient was conscious with oxygen saturation of 97%. The patient did not have cough or shortness of breath. The ECG (Fig. 1(C)), CT scan (Fig. 2(C)) and clinical variables (Table 1) were fully described. The neonate was born via cephalic neonatal delivery with an Apgar score of 9.8. Both mother and baby were transferred home.

Discussion

Pregnant women with COVID-19 are at risk because of both the pregnant woman and the foetus. Fortunately, all the pregnant women we describe here were successfully treated, and no deaths have been reported.

As reported previously, COVID-19 infection has various signs and symptoms, which may be divided into four groups [7,8]. The first is asymptomatic infection with a positive real-time PCR test result, but there are no clinical symptoms and imaging examinations are normal. The second is acute upper respiratory tract infection; in these patients, only fever, cough, pharyngeal pain, nasal obstruction, fatigue, headache, myalgia or discomfort are observed. No pneumonia is evident via imaging examination. The third is mild pneumonia, which may be reported with or without fever but which is accompanied by respiratory symptoms. The fourth and final group has severe pneumonia; they may have oxygen saturation <92% as well as manifestations of anoxia, cyanosis, apnoea, drowsiness, coma,

feeding difficulty and signs of dehydration [9]. Although pregnancy has been described as appearing with a high risk of infection [10], none of our studied cases was severe. In addition, some of our patients had abdominal pain [11]. However, this type of pain is not common in patients with COVID-19 infection.

This study had several limitations. We examined only hospitalized women; we could not obtain information regarding outpatient pregnant women. If we had been able to assess them, we could have compared the results of the two groups.

Conclusion

Pregnant women are in a group at high risk of COVID-19 and should be screened immediately. If infected, they should be isolated until recovery.

Conflict of interest

None declared.

Acknowledgements

This research was approved by the Vice Chancellor for Research and Technology, Ilam University of Medical Sciences. The authors thank the staff of Shahid Mostafa Khomeini of Ilam Educational Medical Center for the necessary cooperation to obtain patient information.

References

- [1] World Health Organization (WHO). Coronavirus disease (COVID-19) pandemic. Available at: <https://www.who.int/emergencies/diseases/novel-coronavirus-2019>.
- [2] Liu H, Wang LL, Zhao SJ, Kwak-Kim J, Mor G, Liao AH. Why are pregnant women susceptible to viral infection: an immunological viewpoint? *J Reprod Immunol* 2020.
- [3] Heymann DL, Shindo N. COVID-19: what is next for public health? *Lancet* 2020;395(10224):542–5.
- [4] Corman VM, Landt O, Kaiser M, Molenkamp R, Meijer A, Chu DK, et al. Detection of 2019 novel coronavirus (2019-nCoV) by real-time RT-PCR. *Eurosurveillance* 2020.
- [5] Mor G, Cardenas I, Abrahams V, Guller S. Inflammation and pregnancy: the role of the immune system at the implantation site. *Ann NY Acad Sci* 2011;1221:80.
- [6] Chen H, Guo J, Wang C, Luo F, Yu X, Zhang W, et al. Clinical characteristics and intrauterine vertical transmission potential of COVID-19 infection in nine pregnant women: a retrospective review of medical records. *Lancet* 2020;395(10226):809–15.

- [7] Shen K, Yang Y, Wang T, Zhao D, Jiang Y, Jin R, et al. Diagnosis, treatment, and prevention of 2019 novel coronavirus infection in children: experts' consensus statement. *World J Pediatr* 2020.
- [8] Li Y, Guo F, Cao Y, Li L, Guo Y. Insight into COVID-2019 for pediatricians. *Pediatr Pulmonol* 2020.
- [9] Huang WH, Teng LC, Yeh TK, Chen YJ, Lo WJ, Wu MJ, et al. 2019 novel coronavirus disease (COVID-19) in Taiwan: reports of two cases from Wuhan, China. *J Microbiol Immunol Infect* 2020.
- [10] Rasmussen SA, Smulian JC, Lednicky JA, Wen TS, Jamieson DJ. Coronavirus disease 2019 (COVID-19) and pregnancy: what obstetricians need to know. *Am J Obstet Gynecol* 2020.
- [11] Schwartz DA. An analysis of 38 pregnant women with COVID-19, their newborn infants, and maternal–fetal transmission of SARS-CoV-2: maternal coronavirus infections and pregnancy outcomes. *Arch Pathol Lab Med* 2020.