



## ORIGINAL ARTICLE

## The Study of the Effectiveness of a Mixture of *Arnebia euochroma* and Gum Extract in Animal Oils and Comparing It with Honey in Diabetic Foot Ulcer

Ali Sharifi<sup>1</sup>, Elham Shafiei<sup>\*2</sup>, Morteza Hosseinzadeh<sup>3</sup>

<sup>1</sup>Department of Internal Medicine, Faculty of Medicine, Ilam University of Medical Sciences, Ilam, Iran

<sup>2</sup>Clinical Research Development Unit, Mostafa Khomeini Hospital, Ilam University of Medical Sciences, Ilam, Iran

<sup>3</sup>Department of Immunology, Faculty of Medicine, Ilam University of Medical Sciences, Ilam, Iran

(Received: 23 April 2019

Accepted: 1 June 2019)

## KEYWORDS

Diabetic Foot Ulcer;  
Arnebia euochroma  
Plant;  
Honey;  
Gum Wax

**ABSTRACT:** One of the most important causes of disability in diabetic patients is diabetic foot ulcers. Native use of medicinal herbs may significantly affect the wound healing process. In this study, a mixture of *Arnebia euochroma* extracts and essential oil of *Pistacia Atlantica* in animal oil used for healing diabetic wounds was compared with natural honey. Thirty male Wistar rats weighing 250 g became diabetic. Wounds of equal size were created in their back area and the wound was dressed with a mixture of *Arnebia euochroma* and essential oil of *Pistacia Atlantica* in animal oil. Afterward, their recovery process was photographed daily. Finally, when we saw evidence of rats' wound healing; we killed rats and searched tissue granulation and epithelialization process. The study results showed that *Arnebia euochroma* and gum mixture at a concentration of 5% of animal oils was more effective compared to honey. Local and regional experiences can be a good source to access pharmaceutical products and services for patients, a scientific reason for this study. We found a more effective ointment for wound dressing. It can help diabetic patients. The oral forms of these plants are recommended to be provided.

## INTRODUCTION

Diabetes is one of the metabolic diseases with increasingly rising incidence and it is expected to happen by the rate of 4.4% worldwide annually by 2030 [1]. One of the important complications of this disease is diabetic ulcer with a risk of 25 percent, which may lead to amputation in approximately 15% of patients [2]. This complication of diabetes has involved approximately 15-25 percent of sanitation costs in advanced countries [3].

Several methods exist to control this condition, one of which is using herbal medicines [4].

Since ancient times, herbal medicines have played a crucial role in the treatment of diseases, and they are

extremely important in the treatment of diseases [5]. According to the World Health Organization, around 80% of the world's population uses medicinal plants at least to meet their basic health needs [6]. This is due to various beliefs and cultural norms, including the use of natural products, past experiences, and belief in the harmlessness of medicinal plants [7].

Although for many years, various medicinal plants have been used based on the main sources of traditional medicine such as Avicenna's Canon of Medicine, Razi's Al-Hawi, and many experiences and traditions of the past, the effectiveness of their possible toxic effects is still unclear [8].

In 2008, Ranjbar et al. introduced the herbal extracts of *melilotus officinalis*, called ANGIPARS, as topical and intravenous medication, and as a new treatment superior to other treatments for different types of ulcers, including diabetes mellitus, and suggested that this drug causes wound healing within a month through pro-angiogenic mechanism [9].

In a clinical trial in 2012, at the Endocrinology and Metabolism Research Center of Tehran University of Medical Sciences, Aalaa et al. found that an ointment and oral forms of ANGIPARS obtained from *melilotus officinalis* had anti-inflammatory and microvascularization effects, and was introduced as a common treatment for diabetic foot ulcer, especially in refractory cases [10].

The mixture of NIKA olive and honey cream is an herbal ointment for treating various types of pressure ulcers, diabetic wounds, burns, or other types of wounds, produced by Iranian Traditional Medicine Products Manufacturing Co and tested by Rashidi et al. They used this ointment for wound dressing of diabetic Wistar rats compared to control group and Phenytoin 1% cream and demonstrated that healing effect of NIKA cream was significantly ( $P < 0.001$ ) better than that in the control group and those dressing with phenytoin 1% [11, 12].

Phenytoin is an anticonvulsant medication. The topical form of phenytoin is a cream used for dressing a variety of chronic wounds, including diabetic foot ulcers, reducing exudate and microbial content and can progress healing [13].

One of topical therapies for infected diabetic foot ulcer is silver containing dressing; e.g. silver seal hydrogel dressing; unfortunately there is no randomized or controlled clinical trial for evaluation of this type of dress [14].

In western areas of Iran, *Arnebia euchroma* root is widely used with different names and is sometimes combined with other plants in the dressing of various types of ulcers [15]. According to the research, the plant contains compounds such as chikonin alkanin isohexin and ester derivatives possessing proven antibacterial and anti-inflammatory effects [16]. Furthermore, Gum is from Van Persia family with anti-inflammatory and anti-bacterial effects, used as ointment in some regions of Iran [17].

There has been some scattered research on these two plants, but there is no single study on their composition. Additionally, there is a good subject to experience ensuring the safety and effectiveness of the combination of these plants is a scientific issue and conducting research to document the experiences that can be a considerable step toward reviving their experiences and providing patients with health. The aim of this study was to investigate the efficacy of *Arnebia euchroma* and Van gum in combination with animal oil on the wound of diabetic rats compared to natural honey.

## MATERIALS AND METHODS

### *Animals*

Adult rats weighing 250 gr were kept in the nest of animal under standard conditions (12 hours of light, 12 hours of darkness, 50-55% humidity and  $2 \pm 2^\circ\text{C}$ ) and easy access to water and food.

All experiments were approved according to the statute of the Ethical Committee for Animal and conducted by Ilam Research Center, Iran.

Rats were randomly divided into five groups:

Control group: Dressed with Eucerin

Group 2: Dressed with *Arnebia euchroma* extract 10% in Eucerin

Group 3: Dressed with *Arnebia euchroma* extract and essential oil of *Pistacia Atlantica* at 5% concentration in animal oil

Group 4: Dressed with *Arnebia euchroma* Plant and Van Waste at 10% Concentration in Animal Oil

Group 5: Dressed with *Arnebia euchroma* extract and Van Wig at 10% concentration in Eucerin

Group 6: Dressed with honey

### *The plant's root containing Arnebia euchroma pigment*

In a rural area in the north of Ilam province, the plants were collected and kept at room temperature and dried to be ground into powder; then, the extracts were taken with the cooperation of the Central Laboratory of Ilam University of Medical Sciences. Afterwards, gum veneer was prepared and extracted at the desired concentration.

To prepare the alcoholic extract of this plant, 100g of plants' powder was mixed with absolute ethanol at a ratio of 5: 1 and was placed on the rout for 24 hours.

Then, the impurities in the extract were separated by paper filter and the extract was centrifuged at 2500 RPM for 20 minutes at 4°C. It was transferred to the distillation apparatus to remove the desired solvents. Finally, a concentrated extract was obtained using microbial filters. The obtained extracts were sterilized using 4.5-micron microbial filters and divided into 1.5 ml micro-tubes and stored at -80°C.

#### **How to make diabetes in rats**

Thirty Wistar rats weighing 250 grams became diabetic using alloxan. Wounds of equal size were created in the back area and their recovery process was photographed daily. Finally, after observing apparent evidence of rats' healing, they were killed after anesthesia and examined for formation of granulation and epithelialization process; Table 1 presents the results.

#### **Examining cytotoxic effects**

Vero cells were used to study cytotoxic effects of the plant using standard MTT and RPMI and 10% serum. When a concentration of 0.1 in the alcoholic extract was determined, it had cytotoxic effects; lower concentrations were used to investigate the effect of extracts on Staphylococcus and Pseudomonas bacteria caused by diabetic ulcers in in-vitro and in-vivo conditions.

## **RESULTS**

In the control group, complete wound healing was observed on the 13<sup>th</sup> day with the formation of epithelium. The epithelial thickness at this time was approximately 79 µm (G1).

In the group treated with 10% A. euchroma with Eucerin, the complete restoration was observed on the 11th day and the epithelial thickness was 102 µm (G2).

In the mixture of Arnebia 5% and essential oil of Pistacia Atlantica 5% and animal oil, complete restoration occurred on the ninth day with an epithelial thickness of 183 (G3).

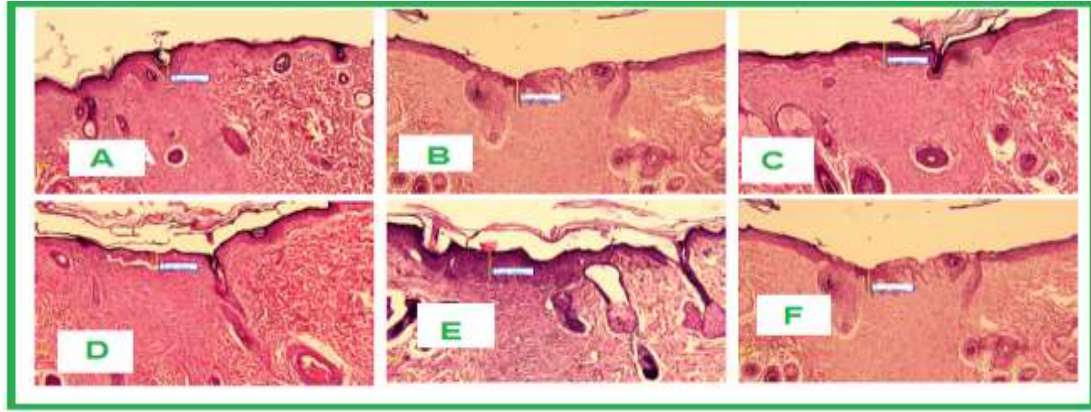
In the group treated with the mixture of Arenbi and gum extract at a concentration of 10% in animal oil, complete restoration was observed after 17 days and the epithelial thickness was 126 µm (G4).

In treatments with the mixture of Arnebia and gum extract with Eucerin at the concentration of 10%, complete restoration was observed on the 13<sup>th</sup> day and epithelial thickness was 109 µm (G5).

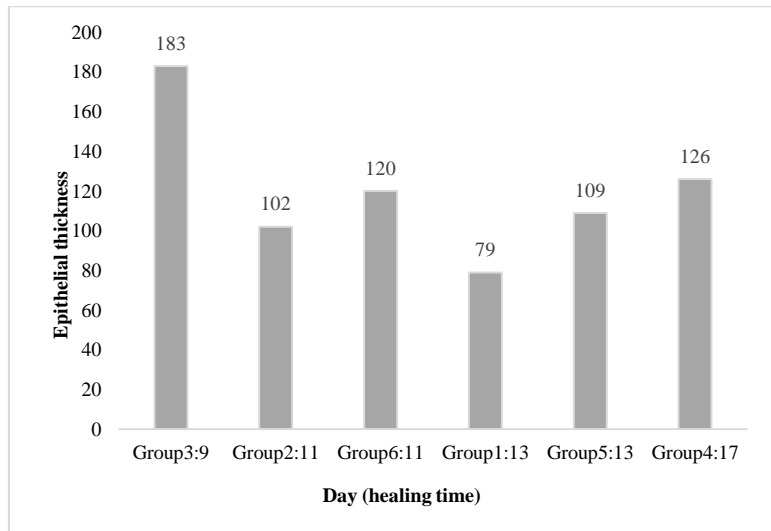
Finally, the honey-dressed group was completely restored on the 11th day and the epithelial thickness was 120 µm (G6). (Table1) (Figures 1 & 2)

**Table 1.** The epithelial thickness and time of healing in groups

	<b>Group 1</b>	<b>Group 2</b>	<b>Group 3</b>	<b>Group 4</b>	<b>Group 5</b>	<b>Group 6</b>
	Treated with eucerin as negative control	Treated with 10% A. euchroma with eucerin	Treated with 5% A. euchroma plus 5% P atlantica with natural cow oil	Treated with 10% A. euchroma plus 10% P Atlantica with natural cow oil	Treated with 10% A. euchroma plus 10% P Atlantica with eucerin	<b>Treated with honey</b>
<b>Epithelial thickness micrometer (Mm)</b>	79	102	183	126	109	120
<b>day of repair</b>	13th	11th	9 <sup>th</sup>	17th	13th	11 <sup>th</sup>



**Figure 1.** Histopathological comparison of tissue samples; A: Epithelial thickness on 9<sup>th</sup> day in Group 3; B: Thickness of epithelial tissue on the 17<sup>th</sup> day in Group 4; C: Epithelial tissue thickness on the 13<sup>th</sup> day in Group 5; D: Thickness of epithelial tissue on the 11<sup>th</sup> day in Group 6; E: Thickness of epithelial tissue on the 11<sup>th</sup> day in Group G2; F: Epithelial thickness on the 13<sup>th</sup> day in Group 1



**Figure 2.** The epithelial thickness and healing time in groups

## DISCUSSION AND CONCLUSIONS

This study was aimed at using native herb extracts from *Arnebia euochroma* and essential oil of *Pistacia Atlantica* in animal oils to heal diabetic ulcers compared to natural honey in an animal model.

The extract of *Arnebia euochroma*'s roots has an anti-inflammatory effect and induces proliferation of fibroblasts, neovascularization, and collagen [18]. The root extract has also been shown to increase epithelialization, collagen synthesis, fibroblasts, and extracellular matrix (RAF) [19].

Hydroquinone extract of *Arnebia euochroma* rich in naphthoquinones, alkanes, and chiconis has been shown to have anti-inflammatory, anti-bacterial, and anti-fungal effects in wound healing [20].

In this study, the thickness of epithelial tissue was investigated in the treatment of diabetic ulcer in rats. The study results revealed that with 5% *Arnebia euochroma* and 5% gum in animal oil, complete restoration was observed on the 9<sup>th</sup> day with epithelial thickness of 183, being higher than other treatment methods. In addition, Xiong et al. reported an anti-inflammatory effect of *Arnebia euochroma* and its significant effect on fibroblast proliferation and collagen synthesis in wound healing [21].

Moreover, the study results showed that the restorative properties of *Arnebia euochroma* ointment were almost equivalent to those of natural honey; however, when combined with essential oil of *Pistacia Atlantica* extract

at a concentration of 5% and animal oil, its effect was much more profound, leading to a much faster recovery. During the treatment, there was no complication causing the discontinuation of treatment. Furthermore, no sensitivity was observed indicating the synergistic effect of *Arnebia euochroma* extract, and gum extract of vena and animal oils were used traditionally.

Animal oils, with unsaturated fatty acids, have been traditionally used to treat burn wounds for many years [22]. Although the mechanism of topical use of this type of oil for wound healing is not clear, the presence of omega-3 fatty acids and vitamins A and D in it and decreased inflammation as well as compensating for the deficiency of essential fatty acids cause normal skin proliferation [23].

Our study, consistent with other studies, suggests that general belief in traditional medicine in the west of Iran can be useful in the treatment of diabetic foot ulcers [24, 25]. Thus, if this plant is effective in wound healing, it provides an oral form to investigate its effects on human specimens and progress toward technology development in our country.

#### ACKNOWLEDGEMENTS

We thank our colleagues at Clinical Research Development Unit, Mostafa Khomeini Hospital who provided insight and expertise that greatly assisted the research.

#### REFERENCES

1. Athyros V. G., Katsiki N., Karagiannis A., Mikhailidis D. P., 2015. High-intensity statin therapy and regression of coronary atherosclerosis in patients with diabetes mellitus. *J Diabetes Complications*. 29(1), 142-145.
2. Wang C., Li L., Wang L., Ping Z., Flory M. T., Wang G., Xi Y., Li W., 2013. Evaluating the risk of type 2 diabetes mellitus using artificial neural network: An effective classification approach. *Diabetes Res Clin Pract*. 100(1), 111-118.
3. Shankaracharya, Odedra D., Samanta S., Vidyarthi A. S., 2010. Computational intelligence in early diabetes diagnosis: a review. *Rev Diabet Stud*. 7(4), 252-262.
4. Galehdari H., Negahdari S., Kesmati M., Rezaie A., Shariati G., 2016. Effect of the herbal mixture composed of Aloe Vera, Henna, *Adiantum capillus-veneris*, and Myrrha on wound healing in streptozotocin-induced diabetic rats. *BMC Complement Altern Med*. 16 (1), 386.
5. Lu L. L., Wan P., Li L. Z., Zhao M. J., Hu J. Y., Zhao Y. F., 2013. Experimental study on topical treatment of diabetic skin ulcers with yi medicine "yi bu a jie" extract. *Chin J Integr Med*. 19(6), 464-467.
6. Budovsky A., Yarmolinsky L., Ben-Shabat S., 2015. Effect of medicinal plants on wound healing. *Wound Repair Regen*. 23(2), 171-183.
7. Ho T. J., Jiang S. J., Lin G. H., Li T. S., Yiin L. M., Yang J. S., Hsieh M. C., Wu C. C., Lin J. G., Chen H. P., 2016. The In Vitro and In Vivo Wound Healing Properties of the Chinese Herbal Medicine "Jinchuang Ointment". *Evid Based Complement Alternat Med*. 2016, 1654056.
8. Khodavaisy S., Rezaie S., Noorbakhsh F., Baghdadi E., Sharifynia S., Aala F., 2016. Effects of *Pistacia atlantica* subsp. *kurdica* on Growth and Aflatoxin Production by *Aspergillus parasiticus*. *Jundishapur J Microbiol*. 9(7), e35452.
9. Ranjbar H.J.D.J.O.P.S., 2008. Overview of diabetic foot; novel treatments in diabetic foot ulcer. 16 (Suppl. 1), 1-6.
10. Aalaa M., Heshmat R., Larijani B., Mohajeri-Tehrani M. J. D., 2012. Smelil (ANGIPARS™) as a New Herbal Drug on Diabetic Foot Ulcer. *J Biomol Res Ther*: e104. doi: 10.4172/2167-7956.1000 e104 Page 2 of 2 Volume 1, Issue 2, 1000e104 *J Biomol Res Ther* ISSN: 2167-7956 JBMRT, an open access journal htakar AA, et al.(2008) Assessment of maximum tolerated dose of a new herba l drug, Semelil (ANGIPARS™) in patients with diabetic foot ulcer: A Phase I clinical trial. 16, 25-30.
11. Rouhipour N., Hayatshahi A., Nikoo M. K., Yazdi N. M., Heshmat R., Qorbani M., 2012. Clinical microbiology study of diabetic foot ulcer in Iran; pathogens and antibacterial susceptibility. *Afr J Microbiol Res*. 6(27), 5601-5608.
12. Rashidi M. K., Mirazi N., Hosseini A., 2016. Effect of topical mixture of honey, royal jelly and olive oil-propolis extract on skin wound healing in diabetic rats. *Wound Medicine*. 12, 6-9.
13. Shaw J., Hughes C., Lagan K., Bell P., 2007. The clinical effect of topical phenytoin on wound healing: a

- systematic review. *British Journal of Dermatology*. 157 (5), 997-1004.
14. Bergin S. M., Wraight P., 2006. Silver based wound dressings and topical agents for treating diabetic foot ulcers. *Cochrane Database Syst Rev*(1), Cd005082.
15. Aliasl J., Barikbin B., Khoshzaban F., Naseri M., Sedaghat R., Kamalinejad M., Talei D., Emadi F., Akbari Z., Aliasl F., Jalaly N.Y., Mohseni-Moghaddam P., 2015. Effect of *Arnebia euchroma* ointment on post-laser wound healing in rats. *J Cosmet Laser Ther*. 17 (1), 41-45.
16. Fan H.Y., Zhang Z.L., Liu K., Yang M.Y., Lv W.H., Che X., Xu H., Song W.W., 2013. Effectiveness of a hydroxynaphthoquinone fraction from *Arnebia euchroma* in rats with experimental colitis. *World J Gastroenterol*. 19(48), 9318-9327.
17. Bahramnejad B., 2014. Identification and characterization of a NBS-LRR class resistance gene analog in *Pistacia atlantica* subsp. *Kurdica*. *Mol Biol Res Commun*. 3(3), 175-185.
18. Ou Y.Y., Jiang Y., Li H., Zhang Y.Y., Lu Y., Chen D. F., 2017. Polysaccharides from *Arnebia euchroma* Ameliorated Endotoxic Fever and Acute Lung Injury in Rats Through Inhibiting Complement System. *Inflammation*. 40(1), 275-284.
19. Fan H., Yang M., Che X., Zhang Z., Xu H., Liu K., Meng Q., 2012. Activity study of a hydroxynaphthoquinone fraction from *Arnebia euchroma* in experimental arthritis. *Fitoterapia*. 83(7), 1226-1237.
20. Singh B., Sahu P., Jain S., Singh S., 2004. Estimation of naphthaquinones from *Arnebia hispidissima* (Lehm.) DC. in vivo and in vitro. I. anti-inflammatory screening. *Phytotherapy Research*. 18(2), 154-159.
21. Xiong W., Luo G., Zhou L., Zeng Y., Yang W., 2009. In vitro and in vivo antitumor effects of acetylshikonin isolated from *Arnebia euchroma* (Royle) Johnston (Ruanzicao) cell suspension cultures. *Chinese medicine*. 4(1), 14.
22. Li Z., Wang J., Ren J., Yi Z., 2004. Effects of topical emu oil on wound healing in scalded rats. *Di 1 jun yi da xue xue bao= Academic Journal of the First Medical College of PLA*. 24(11), 1255-1256.
23. Desbois A.P., Smith V.J., 2010. Antibacterial free fatty acids: activities, mechanisms of action and biotechnological potential. *Applied Microbiology and Biotechnology*. 85(6), 1629-1642.
24. Reza F., Javad T., Haddad K. M. H., 2008. Chemical Composition and Oxidative Stability of Kernel Oils from Two Current Subspecies of *Pistacia atlantica* in Iran. *Journal of the American Oil Chemists' Society*. 85(8), 723.
25. Kiadaliri A. A., Najafi B., Mirmalek-Sani M., 2013. Quality of life in people with diabetes: a systematic review of studies in Iran. *Journal of Diabetes & Metabolic Disorders*. 12(1), 54.